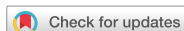

## Letter to the Editor



## OPEN ACCESS

**Received:** Jul 1, 2018  
**Revised:** Jul 1, 2018  
**Accepted:** Jul 12, 2018

### Correspondence to






**SangYun Kim, MD, PhD**

Department of Neurology, Seoul National University College of Medicine and Clinical Neuroscience Center, Seoul National University Bundang Hospital, 82 Gumi-ro 173-beon-gil, Bundang-gu, Seongnam 13620, Korea.  
E-mail: neuroksy@snu.ac.kr

© 2018 Korean Dementia Association

This is an Open Access article distributed under the terms of the Creative Commons Attribution Non-Commercial License (<https://creativecommons.org/licenses/by-nc/4.0/>) which permits unrestricted non-commercial use, distribution, and reproduction in any medium, provided the original work is properly cited.

### ORCID iDs

Mi Jin Oh   
<https://orcid.org/0000-0002-5886-7868>  
SangYun Kim   
<https://orcid.org/0000-0002-9101-5704>  
Young Ho Park   
<https://orcid.org/0000-0002-2756-1786>  
Jeewon Suh   
<https://orcid.org/0000-0003-3509-6447>  
SangHak Yi   
<https://orcid.org/0000-0002-2701-9807>

### Conflict of Interest

The authors have no financial conflicts of interest.

### Author Contributions

Conceptualization: Kim SY; Investigation: Kim SY; Supervision: Kim SY; Writing - original draft: Oh MJ; Writing - review & editing: Kim SY, Park YH, Suh J, Yi SH.

# Early Onset Alzheimer's Disease Presenting as Logopenic Primary Progressive Aphasia

Mi Jin Oh <sup>1</sup>, SangYun Kim <sup>2</sup>, Young Ho Park <sup>2</sup>, Jeewon Suh <sup>2</sup>, SangHak Yi <sup>3</sup>

<sup>1</sup>Seoul National University College of Medicine, Seoul, Korea

<sup>2</sup>Department of Neurology, Seoul National University College of Medicine and Clinical Neuroscience Center, Seoul National University Bundang Hospital, Seongnam, Korea

<sup>3</sup>Department of Neurology, Wonkwang University School of Medicine and Regional Cardiocerebrovascular Center, Iksan, Korea

Primary progressive aphasia (PPA) is a clinical syndrome, encompassing a group of patients who show slowly progressing dementia relatively restricted to the language area of the brain.<sup>1</sup> The logopenic variant of PPA is the most recently identified subtype, characterized by slow word retrieval, impaired sentence repetition, and frequent word-finding pauses. On the other hand, motor speech, grammar, and single-word comprehension are often spared.<sup>2</sup> Although logopenic PPA is diagnosed clinically, most cases share an underlying Alzheimer's disease (AD) pathology.<sup>3</sup> In this article, we report on a case of logopenic primary progressive aphasia with AD pathology, which developed into dementia caused by AD in the course of time.

A 59-year-old female patient first visited Seoul National University Bundang Hospital (SNUBH) in September 2015. She first experienced difficulties in finding appropriate words in 2009 and had developed stuttering and slow speech by May 2012. In 2015, she complained of further difficulties in verbal speech. In the clinic, she presented with impaired comprehension and repetition of complex sentences, difficulty in confrontation naming and phonological paraphasia. On the other hand, single-word comprehension, single-word repetition, and object knowledge were spared. Although spontaneous speech was impaired, frank agrammatism was absent. Such a language profile satisfies the diagnostic criteria of logopenic PPA (**Table 1**). Along with the language disturbance, she also complained of memory loss of recent events, difficulties in continuing a task after an interruption, spatial-orientation disturbance, and mild limitation in activities of daily living. Basic neurological examinations revealed no focal neurological signs. She had been previously diagnosed with hypertension, hyperlipidemia, and chronic kidney disease. She received an operation for gastric cancer in 2002, but her vitamin B12 levels (1,376 pg/mL) and folate levels (73 ng/mL) were higher than normal. She is right-handed. She had received college-level education and had previously worked as a dietitian for approximately 2 years.

In the neuropsychological evaluation in 2015, the patient scored 11/30 in Korean version of the Mini-Mental Status Examination (K-MMSE). A detailed neuropsychological study using Seoul Neuropsychological Screening Battery-II (SNSB-II)<sup>4</sup> revealed a marked decline in all five domains, including attention, language and related functions, visuospatial functions, memory, and frontal executive functions (**Table 2**). Especially in the language domain, she showed non-fluent speech, abnormal repetition, and severely impaired confrontation naming. However, comprehension of simple sentences and words was spared.

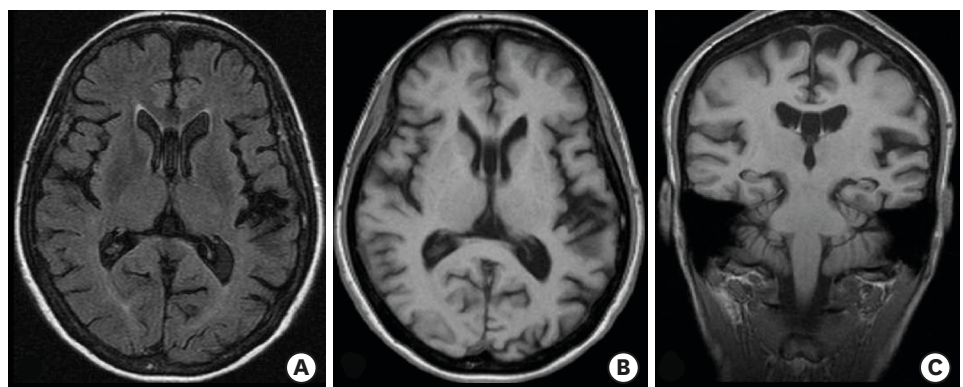
EOAD Presenting as Logopenic PPA

**Table 1.** Diagnostic criteria for logopenic PPA and the diagnosis of the patient

Diagnostic criteria for logopenic PPA <sup>10</sup>	Diagnosis of the patient
<b>I. Clinical diagnosis of logopenic variant PPA</b>	
Both of the following core features must be present	
1. Impaired single-word retrieval in spontaneous speech and naming	0
2. Impaired repetition of sentences and phrases	0
At least three of the following other features must be present:	
1. Speech (phonologic) errors in spontaneous speech and naming	0
2. Spared single-word comprehension and object knowledge	0
3. Spared motor speech	0
4. Absence of frank agrammatism	0
<b>II. Imaging-supported logopenic variant diagnosis</b>	
Both criteria must be present	
1. Clinical diagnosis of logopenic variant PPA	0
2. Imaging must show at least one of the following results:	
A. Predominant left posterior perisylvian or parietal atrophy on MRI	0
B. Predominant left posterior perisylvian or parietal hypoperfusion or hypometabolism on SPECT or PET	0
<b>III. Logopenic variant PPA with definite pathology</b>	
Clinical diagnosis (criterion 1 below) and either criterion 2 or 3 must be present	
1. Clinical diagnosis of logopenic variant PPA	0
2. Histopathological evidence of a specific neurodegenerative pathology (e.g., AD, FTLT-tau, FTLT-TDP, or other)	Positive amyloid-PET, cerebrospinal fluid profile consistent with AD
3. Presence of a known pathological mutation	Not yet

PPA: primary progressive aphasia, MRI: magnetic resonance imaging, SPECT: single-photon-emission computed tomography, PET: positron emission tomography, AD: Alzheimer's disease, FTLT: frontotemporal lobar degeneration, TDP: transactive response DNA-binding protein.

The magnetic resonance imaging (MRI) taken in 2015 showed mild focal brain atrophy, especially in the left superior temporal and left inferior parietal lobules (**Fig. 1**). The fluorodeoxyglucose (FDG)-positron emission tomography (PET) revealed hypometabolism in the frontal, temporal, and parietal cortices, more severe on the left temporal and parietal part (**Fig. 2**). These imaging results showed anatomical and functional degeneration in the temporal and parietal cortices, dominantly in the left hemisphere, which is a typical finding in logopenic PPA patients (**Table 1**). The amyloid-PET results showed symmetric uptake in cortical gray matter of both hemispheres, suggesting the presence of a  $\beta$ -amyloid pathology of AD (**Fig. 3**). The cerebrospinal fluid (CSF) analysis showed low amyloid  $\beta_{1-42}$  (278.1 ng/L), high total tau (534.1 ng/L), and high phosphorylated tau (86.4 ng/L), which is also consistent with the AD profile (cut-off: amyloid  $\beta_{1-42}$  <540 ng/L, total tau >350 ng/L, and phosphorylated tau >60 ng/L).<sup>5,6</sup> Newly diagnosed as early onset Alzheimer's disease (EOAD), she was prescribed donepezil and is under regular follow-up.



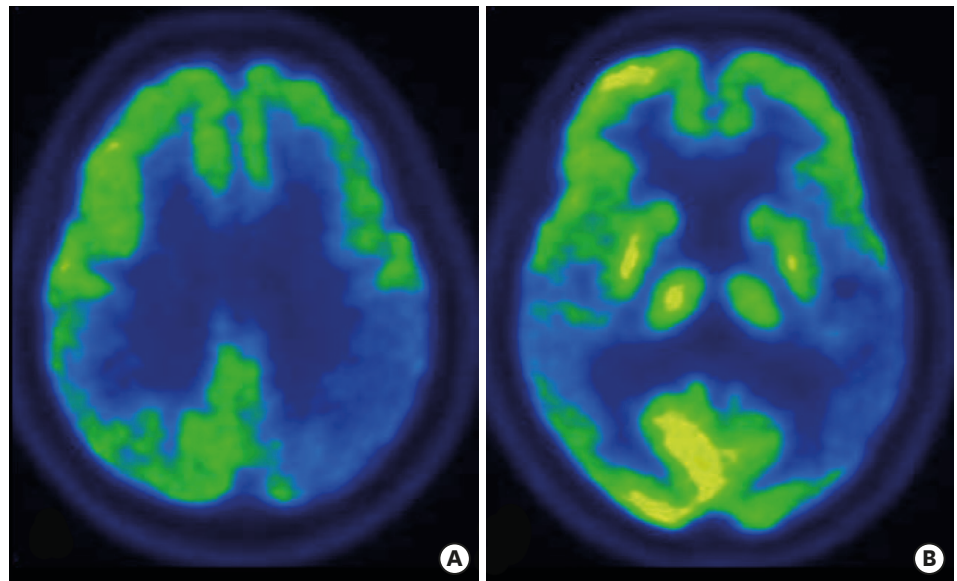
**Fig. 1.** Brain MRI image of the patient taken in October 2015. (A) Axial FLAIR image, (B) axial T1-weighted image, and (C) coronal-oblique T1-weighted image.  
MRI: magnetic resonance imaging, FLAIR: fluid-attenuated inversion recovery.

**Table 2.** Neuropsychological evaluation results in October 2015

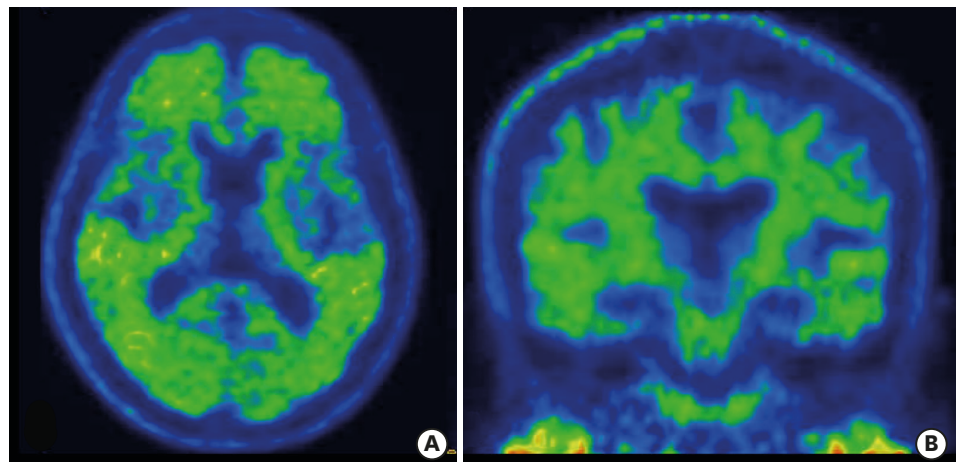
Cognitive domain	Neuropsychological tests	Results
K-MMSE	Score	11 (<0.01%ile)
Attention	Vigilance	Abnormal
	Digit span (forward/backward)	3/2 (0.17/1.68%ile)
	Letter cancellation	Normal
Language and related function	Spontaneous speech	Non-fluent
	Content of speech	Abnormal
	Comprehension	Normal
	Repetition	Abnormal
	Naming	
	K-BNT	12 (<0.01%ile)
	S-K-BNT	3 (<0.01%ile)
	Reading	Normal
	Writing	Abnormal
	Finger naming	Abnormal
	Right-left orientation	Normal
	Body part identification	Normal
	Calculation	8 (<5%ile)
	Praxis	
	Ideomotor	Abnormal
Buccofacial	Normal	
Visuospatial function	Rey CFT copy	
	Score	5 (<0.01%ile)
	Time	453s
Memory	SVLT	
	Free recall	0 (<0.01%ile)
	Delayed recall	0 (0.02%ile)
	Recognition	13 (<0.01%ile)
	Rey CFT copy	
	Immediate recall	0 (0.04%ile)
	Delayed recall	0 (0.02%ile)
Recognition	16 (0.29%ile)	
Frontal/executive function	Motor impersistence	Normal
	Contrasting program	Abnormal
	Go-no-go test	Abnormal
	Fist-edge-palm	Abnormal
	Alternating hand movement	Abnormal
	Alternating square and triangle	Abnormal
	Luria loop	Abnormal
	Semantic word fluency	
	Animal	3 (0.04%ile)
	Supermarket	6 (0.68%ile)
	Phonemic word fluency	
	Total	Could not perform
	Stroop test	
	Word reading (time-per-item)	Could not perform
	Color reading (time-per-item)	Could not perform
Interference	Could not perform	

Tests not included in the SNSB, but added in the SNSB-II.

K-MMSE: Korean version of the Mini-Mental State Examination, K-BNT: Korean version of Boston Naming Test, S-K-BNT: short form of the Korean version of Boston Naming Test, Rey CFT: Rey Complex Figure Test, SVLT: Seoul Verbal Learning Test, SNSB: Seoul Neuropsychological Screening Battery.



**Fig. 2.** FDG-PET image of the patient, taken in December 2015. (A, B) Axial FDG-PET images each in different planes. FDG: fluorodeoxyglucose, PET: positron emission tomography.



**Fig. 3.** Amyloid-PET image of the patient taken in December 2015, showing extended uptake to the cortical gray matter. (A) Axial image and (B) coronal image. PET: positron emission tomography.

Many recent studies have shown that AD pathology is the most common underlying pathology of logopenic PPA. There were several observational studies of logopenic PPA patients that revealed cortical amyloid binding on amyloid-PET and temporoparietal atrophy on MRI,<sup>7,8</sup> and pathological confirmation was made in the study by Mesulam et al.<sup>3</sup> in 2008.

This article discusses a patient who initially presented with language symptoms and was revealed to have an AD pathology shown both by amyloid-PET and CSF analysis. This is a textbook case of an atypical EOAD, which initially presented with language symptoms and was shown to have a language profile and brain-image findings consistent with the logopenic subtype. This case suggests that logopenic PPA and dementia caused by AD can be part of a temporal spectrum of the same pathophysiological process. In conclusion, patients presenting with language symptoms consistent with logopenic PPA should undergo evaluations for AD pathology, and health-care providers should set therapeutic plans accordingly.<sup>9</sup>

## REFERENCES

1. Mesulam MM. Slowly progressive aphasia without generalized dementia. *Ann Neurol* 1982;11:592-598.  
[PUBMED](#) | [CROSSREF](#)
2. Gorno-Tempini ML, Brambati SM, Ginex V, Ogar J, Dronkers NF, Marcone A, et al. The logopenic/phonological variant of primary progressive aphasia. *Neurology* 2008;71:1227-1234.  
[PUBMED](#) | [CROSSREF](#)
3. Mesulam M, Wicklund A, Johnson N, Rogalski E, Léger GC, Rademaker A, et al. Alzheimer and frontotemporal pathology in subsets of primary progressive aphasia. *Ann Neurol* 2008;63:709-719.  
[PUBMED](#) | [CROSSREF](#)
4. Kang YW, Jang SM, Na DL. *Seoul Neuropsychological Screening Battery-II*. Seoul: Human Brain Research & Consulting Co., 2012.
5. Skillbäck T, Farahmand BY, Rosén C, Mattsson N, Nägga K, Kilander L, et al. Cerebrospinal fluid tau and amyloid- $\beta$ 1-42 in patients with dementia. *Brain* 2015;138:2716-2731.  
[PUBMED](#) | [CROSSREF](#)
6. Hansson O, Zetterberg H, Buchhave P, Londos E, Blennow K, Minthon L. Association between CSF biomarkers and incipient Alzheimer's disease in patients with mild cognitive impairment: a follow-up study. *Lancet Neurol* 2006;5:228-234.  
[PUBMED](#) | [CROSSREF](#)
7. Matías-Guiu JA, Cabrera-Martín MN, Moreno-Ramos T, Valles-Salgado M, Fernandez-Matarrubia M, Carreras JL, et al. Amyloid and FDG-PET study of logopenic primary progressive aphasia: evidence for the existence of two subtypes. *J Neurol* 2015;262:1463-1472.  
[PUBMED](#) | [CROSSREF](#)
8. Teichmann M, Kas A, Boutet C, Ferrieux S, Nogues M, Samri D, et al. Deciphering logopenic primary progressive aphasia: a clinical, imaging and biomarker investigation. *Brain* 2013;136:3474-3488.  
[PUBMED](#) | [CROSSREF](#)
9. Henry ML, Gorno-Tempini ML. The logopenic variant of primary progressive aphasia. *Curr Opin Neurol* 2010;23:633-637.  
[PUBMED](#) | [CROSSREF](#)
10. Gorno-Tempini ML, Hillis AE, Weintraub S, Kertesz A, Mendez M, Cappa SF, et al. Classification of primary progressive aphasia and its variants. *Neurology* 2011;76:1006-1014.  
[PUBMED](#) | [CROSSREF](#)